



Breast Center

Villa Tiberia Hospital  
Roma



17<sup>TH</sup> ST.GALLEN INTERNATIONAL  
BREAST CANCER CONFERENCE 2021

## Pre-Pectoral Breast Reconstruction And Complete Implant Coverage With A New Bovine Acellular Pericardium Matrix: Breast Center Villa Tiberia Hospital Experience

*D. Varvaras<sup>\*1</sup>, M.G. Lo Schiavo<sup>2</sup>, V. De Felice<sup>1</sup>, S. Tardioli<sup>3</sup>, G. Papadopoulos<sup>4</sup>,  
G. Trobbiani<sup>5</sup>, R.A. Madaio<sup>6</sup>, H. Nina<sup>7</sup>, T.M.J. Al Lawati<sup>8</sup>.*

<sup>1</sup>Department of Surgery, Villa Tiberia Hospital GVM CARE & RESEARCH, Rome, Italy, <sup>2</sup>Department of Surgery, AO Papardo, Massina, Italy, <sup>3</sup>Department of Radiology, Villa Tiberia Hospital GVM CARE & RESEARCH, Rome, Italy, <sup>4</sup>Euromedica Geniki Kliniki, Thessaloniki, Greece,, <sup>5</sup>Department of Anesthesiology, Villa Tiberia Hospital GVM CARE & RESEARCH, Rome, Italy, <sup>6</sup>Department of Oncology, Ospedale Israelitico, Rome, Italy, <sup>7</sup>University Mother Teresa, Tirana, Albania, <sup>8</sup>Department of Surgery, Royal Hospital, Muscat, Oman

### Background

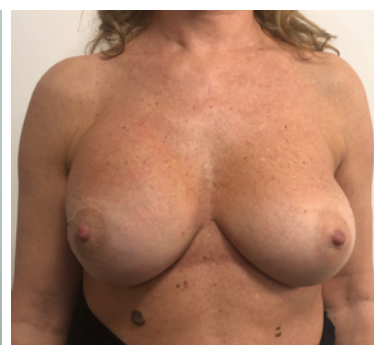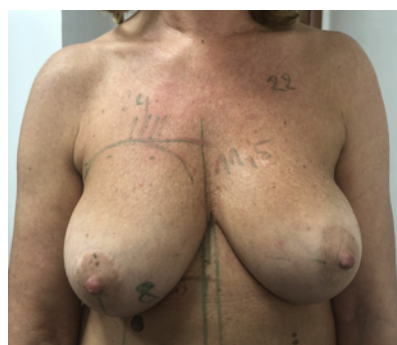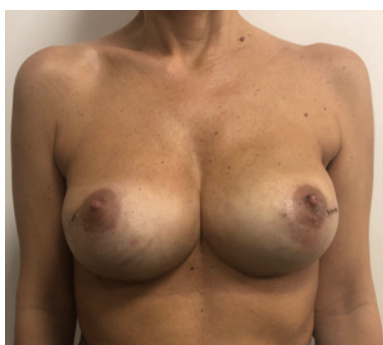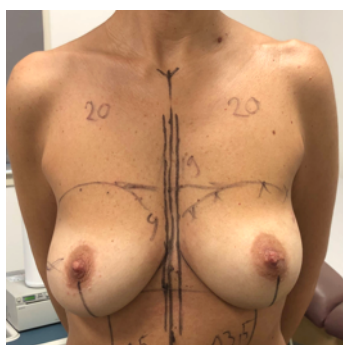
Pre-pectoral breast reconstruction allows to avoid the use of the pectoralis major muscle for implant coverage and to perform a complete wrapping of the prosthesis with a sheet of biological mesh, to prevent the direct contact between the silicone implant and the host tissues and complications such as animation deformity, muscular impairment, and migration of the prosthesis. **This study aims to describe our case series with pre-pectoral implant placement and coverage of it with bovine pericardium-derived matrix named exaSHAPE®.**

### Materials and Methods

A total of 10 women with breast tumors were selected and underwent mono- or bilateral mastectomies and prepectoral breast reconstruction. We used a particular sheet of bovine pericardium-derived biological mesh, especially designed for pre-pectoral implant placement, that make possible to cover the whole front surface and approximately 1/3 of the rear surface of the implant. **This mesh allows a perfect and simple fit, with a lower amount of matrix. This is an important achievement since most of complications, such as seroma and infection, are related to the amount of biological mass used.**

### Results

A total of 16 procedures were retrospectively collected. Mean age was 46.8 years], mean BMI was 22.7 kg/m<sup>2</sup>, and mean follow-up was 16.4 months. Reconstruction was carried out after demolitive surgery for tumor in 80% of the cases, 18% of patients had prophylactic surgery and 2% had revision surgery. Diabetes, smoking, and immunosuppression had an influence on complications occurrence, as well as implant weigh. Of the 10 patients that underwent this procedure, only 2 presented complications that resolved in a maximum of 3 weeks. Capsular contracture was associated with postoperative radiotherapy, but the overall rate of this complication was low (3.1%).



### Conclusion

Pre-pectoral implant positioning allows to obtain less pain, less morbidity and faster recovery, while the percentages of capsular contracture and animation deformity are very rare in all studies. **exaSHAPE® represents a good alternative over other biological meshes.** The need of a very close collaboration between all the specialists involved in breast cancer care is very high, in order to achieve oncological safety and the best aesthetic result. We are at the beginning of a new era in breast reconstruction and our duty is to achieve the best for our patients.